

ADVERTISEMENT

[Home](#)[About](#)[Editors](#)[For authors](#)[For reviewers](#)[Online content](#)[Contact](#)

Content

[List volumes](#) - [List articles in this issue](#)

Adalimumab Treatment for SAPHO Syndrome

Salvador Arias-Santiago¹, Daniel Sanchez-Cano², José Luis Callejas-Rubio², María Antonia Fernández-Pugnaire¹ and NorbertovOrtego-Centeno²¹ Department of Dermatology, and ² Department of Internal Medicine, San Cecilio Clinical Hospital, University of Granada, Av Dr Oloriz 16, ES-18012 Granada, Spain. E-mail: salvadorarias@hotmail.es

Accepted November 10, 2009.

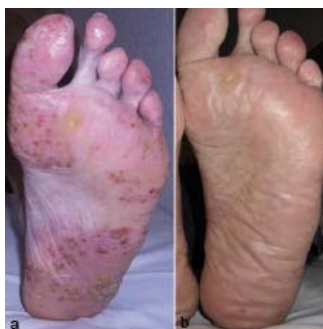SAPHO syndrome is a rare condition of unknown pathogenesis originally described by Chamot et al. (1) in 1987. Onset usually occurs in young adults, with no differences between sexes and it is manifested by synovitis, acne, pustulosis, hyperostosis and osteitis. Of paramount importance is the finding of a non-infectious, inflammatory osteitis associated with skin lesions.

Since there is no accepted universal treatment for SAPHO syndrome, several therapies have been used to treat this disorder, such as non-steroidal anti-inflammatory drugs (NSAIDs), antibiotics, immunosuppressants and immunomodulators, with varying results. Anti-tumour necrosis factor (TNF)- α agents have recently been employed in this syndrome, yielding an excellent response (2).

CASE REPORT

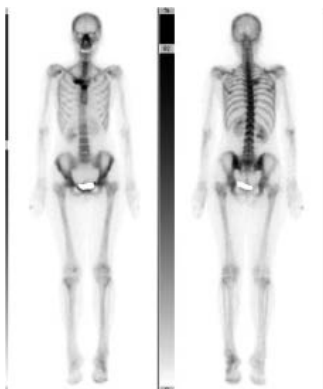
A 49-year-old woman presented with painful, osteoarticular inflammation of her anterior chest wall and right shoulder, as well as recurrent, pustular lesions on the plantar and lateral areas of both feet, more markedly on the left one (Fig. 1a). Her medical history included osteoporosis, hyperlipidaemia, a non-functioning thyroid nodule and an episode of acute arterial ischaemia, which required embolectomy and sympathectomy, followed by a stage II chronic ischaemia (Fontaine's system) of her left leg as a sequel.

Fig. 1. View of pustular lesions on the plantar area of the patient's left foot, (a) before and (b) 5 weeks after treatment with adalimumab.



Laboratory tests, including C-reactive protein, erythrocyte sedimentation rate, viral serology tests and antinuclear antibodies showed no abnormalities. Test for HLA-B27 was negative and a thrombophilia work-up revealed only heterozygosis for the *MTHFR* gene. Bacterial cultures from pustules were negative. Thus, the patient was diagnosed with sterile plantar pustulosis. Thoracic X-ray showed an increased density in the right sternoclavicular joint, and three-phase bone (Tc-99m) and gallium scans revealed a non-infectious uptake in the right sternoclavicular and manubriosternal joints and tarsal bones of her left foot (Fig. 2). A thoracic and abdominal computed tomography (CT) scan revealed no abnormalities. With all these findings fulfilling the diagnostic criteria, SAPHO syndrome was diagnosed.

Fig. 2. A three-phase bone (Tc-99m) scan showing a non-infectious uptake in the right sternoclavicular and manubriosternal joints and tarsal bones of the patient's left foot.



Treatment with NSAIDs was then initiated, yielding a poor response, as well as intrarticular injections of steroids. Also, topical steroids (dobetasol 0.05% ointment) were prescribed for pustular lesions, leading to a slight improvement. Subsequently, treatment with oral prednisone (1 mg/kg body weight/day) and risedronate (35 mg

Share with your friends

Consiglia 0Tweet 0

Actions

[Abstract](#)[Full text](#)[PDF](#)

Supplementary

There is no supplementary for this article.

Print information

Volume 90, Issue 3

DOI: 10.2340/00015555-0822

Pages: 301-302

[View at PubMed](#)

weekly) were added without success. Thus, the patient was started on infliximab, 5 mg/kg body weight on weeks 0, 2 and 6, and every 8 weeks thereafter. This resulted in an improvement in her osteoarticular symptoms after one month. In spite of this, her skin lesions worsened following the initial infusions, developing now also on her palms. Consequently, the patient refused to continue treatment with infliximab and her joint symptoms relapsed.

Adalimumab, a human monoclonal antibody that specifically binds TNF- α (Humira, Abbot Laboratories, Abbot Park, IL, USA) was proposed to the patient as a salvage therapy, being administered subcutaneously at an initial dose of 80 mg weekly for the first 2 weeks, followed by 40 mg every other week thereafter. Adalimumab yielded an excellent response in cutaneous as well as articular symptoms. Improvement started within 2–3 weeks of treatment with adalimumab, the patient being completely free of symptoms after 5 weeks (Fig. 1b). She has remained asymptomatic for over 10 months of follow-up and three-phase bone (Tc-99m) and gallium scans were negative. No adverse events have been observed.

DISCUSSION

One of the following diagnostic criteria must be met in order to make a diagnosis of SAPHO syndrome (3): (i) axial, sterile, recurrent multifocal chronic osteomyelitis with or without dermatosis; (ii) acute, subacute or chronic arthritis associated with palmoplantar pustulosis, pustular psoriasis or severe acne; and (iii) any sterile osteitis in association with palmoplantar pustulosis, pustular psoriasis or severe acne.

Cutaneous manifestations are present in two-thirds of patients and chiefly consist of severe acne (acne fulminans or acne conglobata), pustular psoriasis and palmoplantar pustulosis. Although the pathogenesis of this syndrome remains elusive, high concentrations of TNF- α (3) in bone specimens of patients with SAPHO syndrome have been described recently, and the use of the TNF- α blocking agents (infliximab and etanercept) has been reported (3) with promising results. However, to the best of our knowledge, there is no published experience regarding the use of adalimumab in SAPHO syndrome.

There are 18 patients with SAPHO syndrome reported to have been treated with infliximab in the literature up to the present (4). Response to therapy was excellent in all cases just after the first infusions. In several cases discontinuation of the therapy resulted in relapse. Skin lesions improved in most of the patients. However, two patients with palmoplantar pustulosis presented with exacerbation of their lesions while being on infliximab, and one patient developed these symptoms after initiation of the treatment (4, 5). In our patient, despite the dramatic response to infliximab of her osteoarticular symptoms, skin lesions were non-responsive or even worsened during treatment.

The mechanism by which infliximab induces remission of cutaneous manifestations in some patients and exacerbation in others is unknown. Skin lesions in this syndrome are characterized by the presence of a neutrophilic infiltrate (6). Apparently, in patients with rheumatoid arthritis, infliximab may reduce inflammation by down-regulating membrane-bound proteinase 3 expression in neutrophils, as well as by altering the balance between activating and inhibitor Fc γ receptor type II isoforms (7, 8). Moreover, inhibition of neutrophil chemotaxis by infliximab has been described, which might also contribute to its anti-inflammatory action (9). In addition, a proliferation of *Propionibacterium acnes*, has been proposed as a result of changes in function of neutrophils. (5).

Lee et al. (10) in a case series of 150 patients treated with anti-TNF- α agents for different reasons described the development of palmoplantar pustular psoriasis in three patients treated with these drugs (infliximab, adalimumab and etanercept). In another case series, 120 patients treated with TNF- α blocking agents for a variety of disorders developed some kind of psoriasiform rash, 37 presented with palmoplantar psoriasis (11).

In summary, adalimumab may be an excellent alternative to infliximab to control both skin and osteoarticular lesions in SAPHO syndrome.

REFERENCES

- Chamot AM, Benhamou CL, Kahn MF, Beranek L, Kaplan G, Prost A. Le syndrome pustulose hyperostose osteite (SAPHO). Resultats d'une enquête nationale: 85 observations. Rev Rhum Mal Osteoartic 1987; 54: 187–196.
- Wagner AD, Andresen J, Jendro MC, Hülsemann JL, Zeidler H. Sustained response to tumor necrosis factor alpha-blocking agents in two patients with SAPHO syndrome. Arthritis Rheum 2002; 46: 1965–1968.
- Benhamou CL, Chamot AM, Kahn MF. Synovitis-acne-pustulosis hyperostosis-osteomyelitis syndrome (SAPHO): a new syndrome among the spondyloarthropathies? Clin Exp Rheumatol 1988; 6: 109–112.
- Moll C, Hernández MV, Cañete JD, Gómez-Puerta JA, Soriano A, Collado, et al. Ilium osteitis as the main manifestation of the SAPHO syndrome: response to infliximab therapy and review of the literature. Semin Arthritis Rheum 2008; 37: 299–306.
- Massara A, Cavazzini PL, Trotta F. In SAPHO syndrome anti-TNF-alpha therapy may induce persistent amelioration of osteoarticular complaints, but may exacerbate cutaneous manifestations. Rheumatology 2006; 45: 730–733.
- Kahn MF, Khan MA. The SAPHO syndrome. Baillieres Clin Rheumatol 1994; 8: 333–362.
- Belostocki K, Pricop L, Redecha PB, Aydin A, Leff L, Harrison MJ, et al. Infliximab treatment shifts the balance between stimulatory and inhibitory Fc γ receptor type II isoforms on neutrophils in patients with rheumatoid arthritis. Arthritis Rheum 2008; 58: 384–388.
- Matsumoto T, Kaneko T, Seto M, Wada H, Kobayashi T, Nakatani K, et al. The membrane proteinase 3 expression on neutrophils was downregulated after treatment with infliximab in patients with rheumatoid arthritis. Clin Appl Thromb Hemost 2008; 14: 186–192.
- Pay S, Musaback U, Erdem H, Simsek I, Pekel A, Sengul A, et al. Chimerical anti-TNF-alpha, infliximab, inhibits neutrophil chemotaxis and production of reactive oxygen species by blocking the priming effect of mononuclear cells on neutrophils. Immunopharmacol Immunotoxicol 2005; 27: 187–198.
- Lee HH, Song IH, Friedrich M, Gauliard A, Detert J, Röwert J, et al. Cutaneous side-effects in patients with rheumatic diseases during application of tumour necrosis factor-alpha antagonists. Br J Dermatol 2007; 156: 486–491.
- Wollina U, Hansel G, Koch A, Schönlebe J, Köstler E, Haroske G. Tumor necrosis factor-alpha inhibitor-induced psoriasis or psoriasiform exanthemata: first 120 cases from the literature including a series of six new patients. Am J Clin Dermatol 2008; 9: 1–14.

ABOUT	EDITORS	FOR AUHTORS	FOR REVIEWERS	ONLINE CONTENT	CONTACT
<ul style="list-style-type: none"> • Acta Dermato-Venereologica • ESDaP • IFSI • Advisory Board 	<ul style="list-style-type: none"> • Editors 	<ul style="list-style-type: none"> • Submit a manuscript • Track your manuscript • Instructions 	<ul style="list-style-type: none"> • Manage your reviews 	<ul style="list-style-type: none"> • All issues available online • Published articles by category • Preview of papers in the copy-editing process • Preview of fully accepted papers, still not published in any volume • Subscribe for e-mail alerts • Subscribe to Acta Dermato-Venereologica • Top 20 most viewed 	<ul style="list-style-type: none"> • Helpdesk/create new ticket • Editorial office • Advertise