



Search by :

ANATOMY

GAMUTS

Search...

All Diagnosis Gamuts

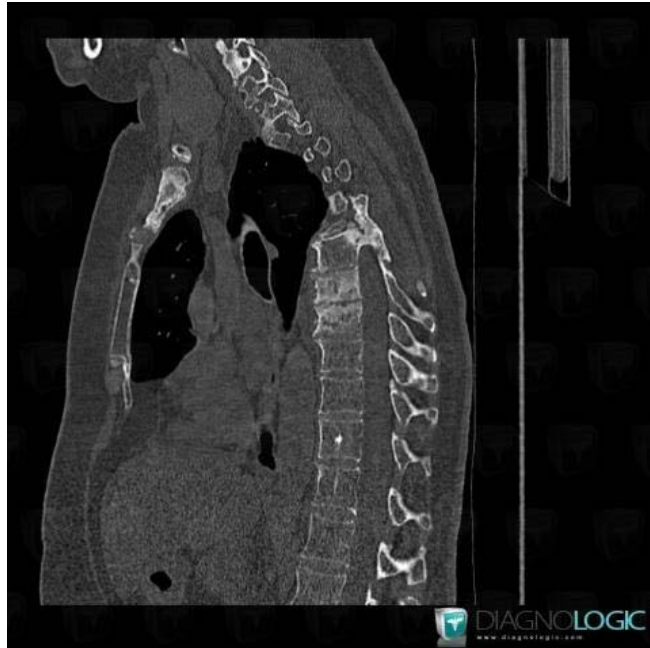Diagnologic is a website dedicated to health care professionals only. The Use of Diagnologic implies acceptance of the [Terms of use](#).

## Folder icon Patient details - Key images

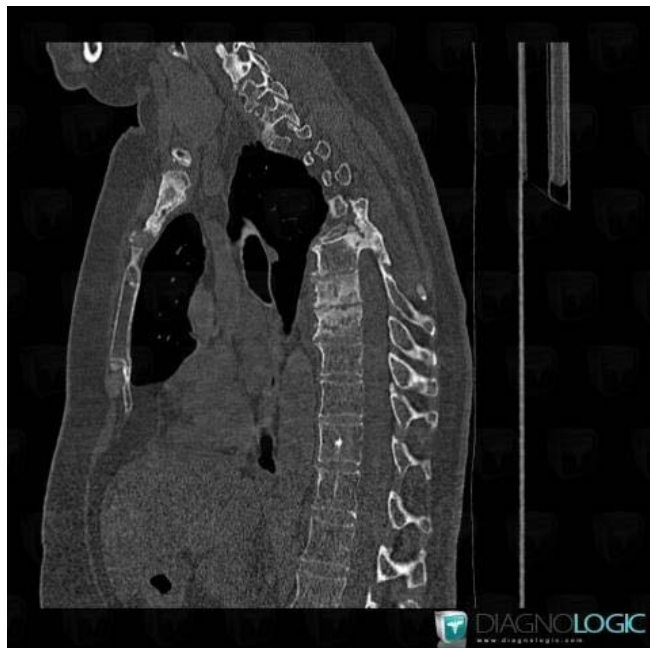[Return to the patient details](#)

The images below illustrate this case for diagnoses **SAPHO syndrome**, for the modalities (CT ,MRI)

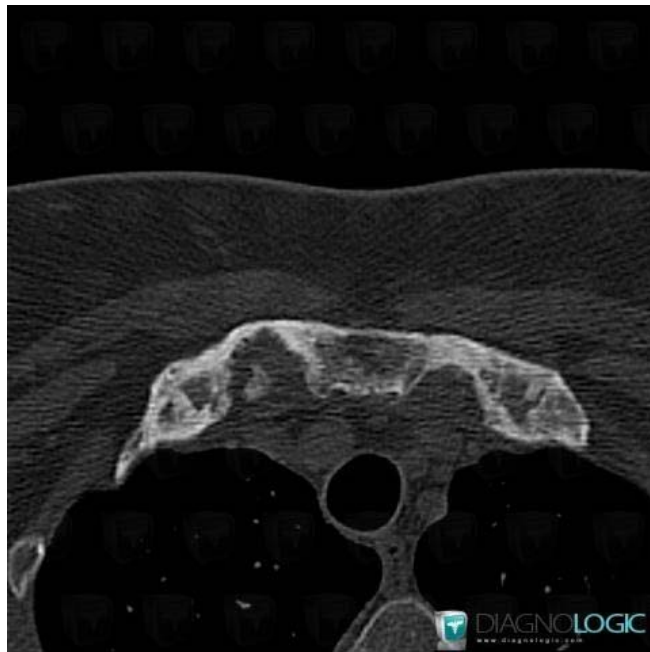Gamuts for this case :  
Focal area of sclerosis in a vertebra  
Without gamut



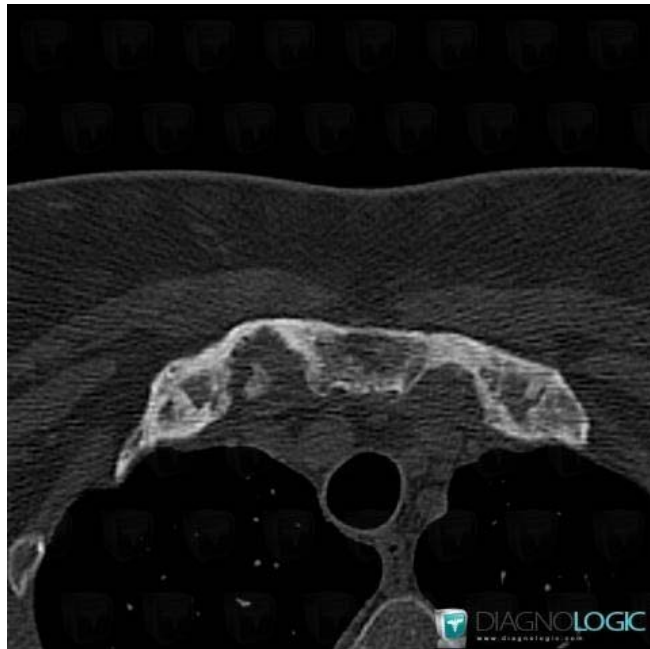Here is the specific information in the key image above:  
- Diagnosis SAPHO syndrome, Location(s) Vertebral body / Disk, with gamuts Focal area of sclerosis in a vertebra



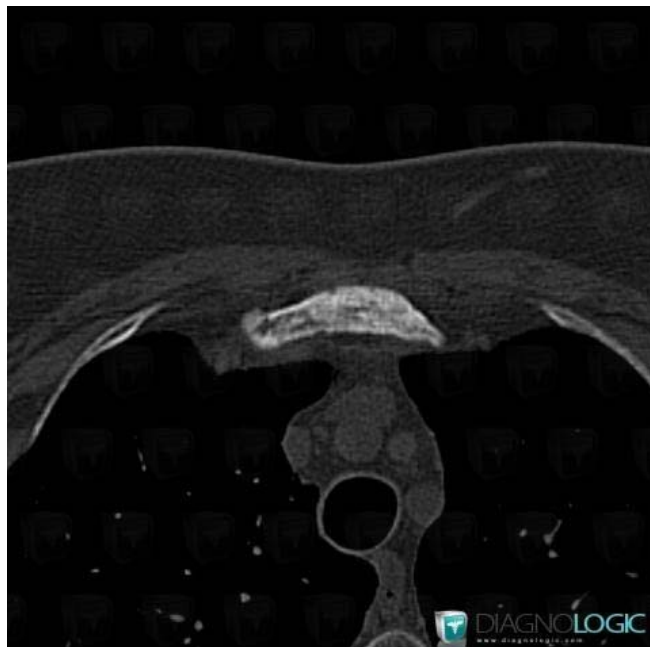Here is the specific information in the key image above:  
- Diagnosis SAPHO syndrome, Location(s) Vertebral body / Disk, with gamuts Focal area of sclerosis in a vertebra



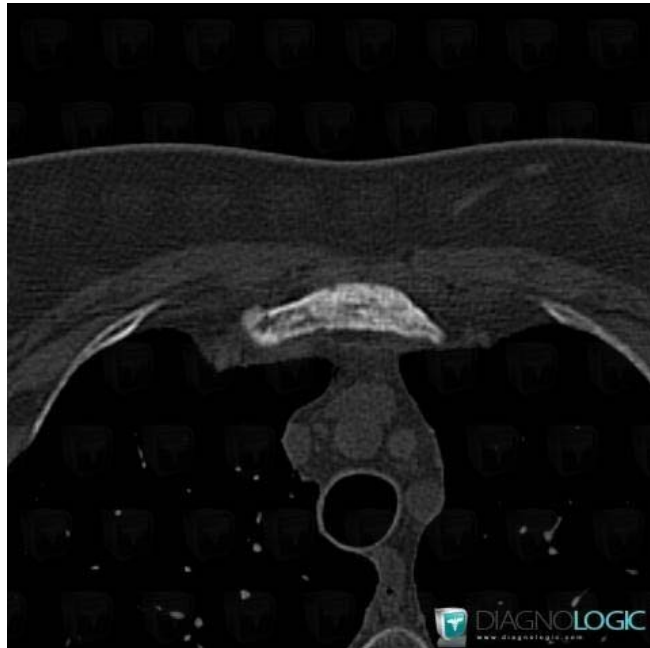
Here is the specific information in the key image above:  
- Diagnosis SAPHO syndrome, Location(s) Costosternal / Sternoclavicular joint and Costal cartilage, with gamuts



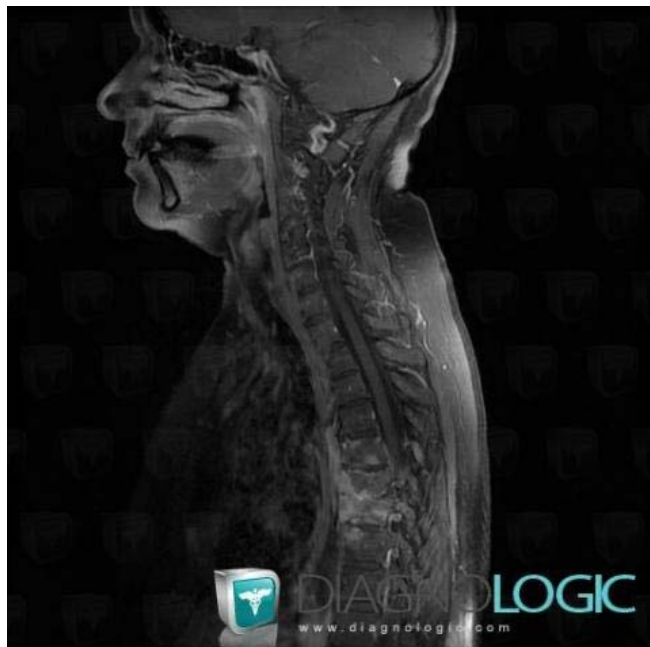Here is the specific information in the key image above:  
- Diagnosis SAPHO syndrome, Location(s) Costosternal / Sternoclavicular joint and Costal cartilage, with gamuts



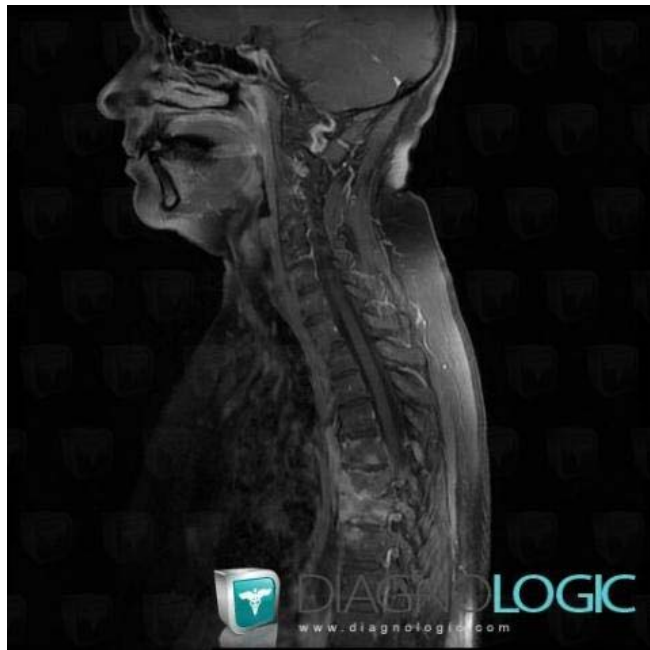Here is the specific information in the key image above:  
- Diagnosis SAPHO syndrome, Location(s) Sternum, with gamuts



Here is the specific information in the key image above:  
- Diagnosis SAPHO syndrome, Location(s) Sternum, with gamuts



Here is the specific information in the key image above:  
- Diagnosis SAPHO syndrome, Location(s) Vertebral body / Disk, with gamuts



Here is the specific information in the key image above:  
- Diagnosis SAPHO syndrome, Location(s) Vertebral body / Disk, with gamuts

